

REVIEW ARTICLE

Difficulty in advancing a tracheal tube over a fiberoptic bronchoscope: incidence, causes and solutions

T. Asai* and K. Shingu

Department of Anaesthesiology, Kansai Medical University, 10-15 Fumizono-cho, Moriguchi City, Osaka 570-8507, Japan

**Corresponding author. E-mail: asait@taki.kmu.ac.jp*

Br J Anaesth 2004; **92**: 870–81

Keywords: equipment, bronchoscopes fiberoptic; equipment, tubes tracheal

Fiberoptic tracheal intubation is a useful technique in patients whose tracheas are difficult to intubate.^{66 69} However, there are two major difficulties with this technique. The first is location of the glottis and insertion of a fibroscope into the trachea. Induction of general anaesthesia (with or without neuromuscular block) causes the soft palate, tongue and epiglottis to approximate to the posterior pharyngeal wall,⁶⁴ and thus little air space is left in the oropharynx for manoeuvring the tip of the fibroscope to locate the glottis.⁵⁸ The second difficulty is insertion of a tube over the fibroscope into the trachea. There have been reports of failed tracheal intubation despite successful insertion of a fibroscope into the trachea.^{67 89}

To solve the first difficulty, several manoeuvres (such as thrusting the jaw forward, extension of the head, or traction of the tongue) have been proposed, and airway intubators (such as the Berman,¹⁷ Ovassapian⁶⁶ and Williams⁸⁷) have been developed. In addition, there have been comprehensive articles discussing effective ways of teaching fibroscopy.^{58 66 69 85} In contrast, there have been no textbooks or reviews which comprehensively deal with the second difficulty, of advancing a tracheal tube over a fibroscope. Therefore, the main aim of this review article is to analyse the incidence of, causes of and possible solution to, the difficulty in advancing a tube over a fibroscope into the trachea.

Problems associated with difficult intubation over a fibroscope

Difficulty in fiberoptic intubation is associated with two major problems. The first is apnoea. Time taken to intubate the trachea, and thus the duration of apnoea, is generally markedly longer for fiberoptic intubation than intubation using a laryngoscope.^{74 80–82} As a consequence, stress

responses, such as the increase in the heart rate and blood pressure, are more likely to be greater during fiberoptic intubation.^{80–82} If apnoea continues unduly, the patient may become hypoxic.⁵⁶ It is particularly awkward if, after successful insertion of a fibroscope into the trachea despite considerable difficulty in a patient with a difficult airway, it is still difficult to advance a tube over the scope into the trachea and the arterial haemoglobin oxygen saturation starts to decrease.

The second problem associated with difficult fiberoptic intubation is damage to the upper airway. Repeated attempts at inserting a fibroscope into the trachea and advancing a tube over the scope increase the risk of injury to the larynx and surrounding tissues, leading to bleeding from, or oedema of, the tissues. Although rare, complete airway obstruction could occur during attempts at fiberoptic intubation even when the patient is not anaesthetized.^{18 59} What tends to be ignored is that at no time during insertion of a tracheal tube over a fibroscope can the tip of the tube be seen directly. Therefore, a tracheal tube should be advanced over a fibroscope with great caution, particularly in patients with pathological changes to the glottis or surrounding tissues.⁴⁴ In a patient with laryngeal papillomatosis, repeated attempts at passing a tube over a successfully inserted fibroscope into the trachea resulted in massive bleeding, necessitating an emergency surgical airway.⁸³

Incidence of difficult intubation over a fibroscope

Adults

The incidence of difficulty in passing a tracheal tube over an orally inserted fibroscope varies considerably between studies, ranging from 0 to 90% (Fig. 1).

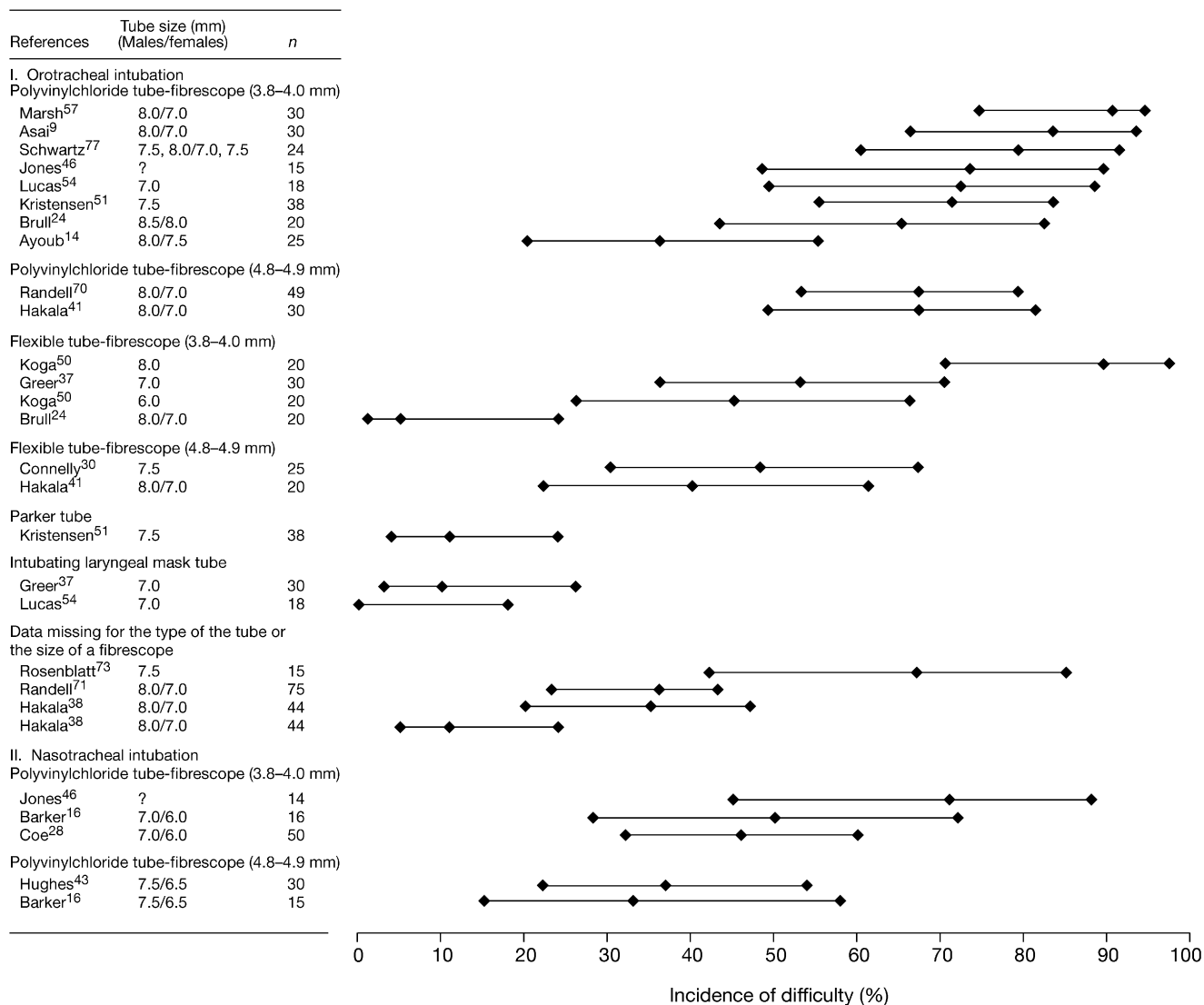


Fig 1 Incidence (and 95% confidence interval) of difficulty in advancing a tracheal tube over a fibreoptic bronchoscope.

Nasal fibreoptic intubation can be as difficult as oral fibreoptic intubation (Fig. 1).^{16 28 43 46} Although differences in the definition of the difficulty between studies might have produced these differences in the incidence, other factors, such as a difference in the size of a fibrescope or in the type and size of a tracheal tube, might also have affected the incidence (Fig. 1). The possible effects of the variable size of a fibrescope and the type and size of a tube on the incidence will be discussed later.

Children

There have been few reports of the ease of fibreoptic intubation in children.^{39 74 88} Hakala and colleagues³⁹

assessed the ease of fibreoptic intubation in 11 children using various sizes of fibrescopes and tubes, and found that the incidence of impingement of the tube was significantly greater in children under 2 yr old (all of four children) than in children aged 2–8 yr (one of seven children).⁴⁰ Wrigley and colleagues⁸⁸ studied 40 children (aged 6 months to 7 yr) who were breathing spontaneously under general anaesthesia, and found that tracheal intubation failed, the fibrescope flipping out of the trachea in seven of 40 (18%) children. In contrast, Roth and colleagues⁷⁴ reported that fibreoptic intubation was possible within 40 s in all of 40 babies studied. It seems premature to conclude that the incidence of difficulty in advancing a tube over a fibrescope is higher in children than in adults.

Table 1 Sites that hamper insertion of a tube over a fibrescope into the trachea

Anatomical factors	
	Narrowed nasal passage
	Enlarged tongue
	Epiglottis
	Arytenoid cartilage
	Pyramidal fossae
	Oesophagus
Device or procedure factors	
	Murphy eye of a tracheal tube
	Airway intubator
	Cricoid pressure
	Jaw thrusting

Causes of difficult intubation over a fibrescope

Main sites of obstruction

The major reason for difficulty in advancing a tube over a fibrescope is considered to be deviation of the course of the tube from that of the fibrescope (because of the gap between the two) towards the epiglottis, arytenoid cartilage, pyramidal fossae or oesophagus (Table 1).^{9 48 63 67 77} There has been no convincing report showing which anatomical site is the main cause for obstruction to the passage of a tracheal tube. Nevertheless, there are several opinions based on limited data.

Oral intubation

By examining the point of obstruction using mannequins, Katsnelson and colleagues⁴⁸ found that the right arytenoid cartilage is the main site which obstructs the passage of a tracheal tube over an orally inserted fibrescope. They also assessed the site of obstruction in patients, and obtained the same result.⁴⁸ Schwartz and colleagues⁷⁷ also found that in all of seven patients in whom passing a tube over an orally inserted fibrescope was difficult, the tip of the tube was impinging on the right arytenoid cartilage. In contrast, Asai and colleagues⁹ found that in seven patients in whom there was difficulty in advancing a tracheal tube over a fibrescope, the tube had migrated into the oesophageal inlet in four patients, and in the remaining three patients the tube was impinging on either the epiglottis or the arytenoid cartilage. The reasons for these discrepancies between studies are not clear, but one possibility is the difference in the observation methods: to assess the site of obstruction, a laryngoscope was inserted in the first two reports, whereas another fibrescope was inserted nasally into the pharynx in the last study. Insertion of a laryngoscope might have altered the anatomy and affected the results. Dogra and colleagues³³ reported that in 13 patients in whom there was difficulty in advancing a tube over a gum elastic bougie, migration of the tube into the oesophageal inlet was the most frequent cause



Fig 2 A precurved tube is advanced over a fibrescope and held with its greater curvature facing down. The bevel of the tube is facing the left and the tip of the tube is on the right. Thus the tip of the tube is more likely to impinge on the right arytenoid cartilage than the left.

(eight patients), and in no patient had the tube impinged on the right arytenoid cartilage. It is possible to conclude that the main reasons for difficulty in advancing a tube over an orally inserted fibrescope is that the tube tends to move posterior to the glottis, such as onto the arytenoid cartilage or into the oesophageal inlet.

There has at least been agreement that the right arytenoid cartilage is more likely than the left arytenoid cartilage to obstruct the passage of a tube.^{9 48 77} This can be explained by the direction of the bevel of a tracheal tube:³¹ when a precurved tube is advanced over a fibrescope, the bevel of the tube is usually facing the left and the tip of the tube is on the right, and thus the tip of the tube is likely to impinge on the right arytenoid cartilage, rather than the left (Fig. 2).

Nasal intubation

For nasal fibreoptic intubation, a narrowed nasal passage, resulting (for instance) from deviation of the nasal septum, a nasal septal spur or mucosal thickening of inflamed turbinates, can be an obstacle to the passage of a tube.^{42 63 67}

Hughes and Smith⁴³ have suggested that the incidence of impingement of a tracheal tube might be greater when the tube is inserted through the right nostril than the left. In their study, the tube was impinged in eight of 15 patients (53%) when it was passed through the right nostril and in three of 15 patients (20%) when it was passed through the left

nostril. Nevertheless, there was no significant difference between groups. It is not known whether there was no clinically meaningful difference between groups or whether the absence of the significance was because of an insufficient number of patients studied (false negative).

Katsnelson and colleagues⁴⁸ claimed, from a study using mannequins, that the epiglottis is the main site (except for the nasal passage) which obstructs the passage of a tube during nasal fibreoptic intubation. They speculated that the difference in sites of obstruction between oral intubation (the right arytenoid cartilage) and nasal intubation (the epiglottis) resulted from the difference in alignment of the oral, pharyngeal and laryngeal axes in oro- and nasotracheal intubation. Nakayama and colleagues⁶³ assessed the site of obstruction in patients for nasal fibreoptic intubation. In contrast to Katsnelson and colleagues, they suggested that the arytenoid cartilage was the main site of obstruction.

Oesophageal intubation

A tracheal tube may be inadvertently inserted into the oesophagus even when a fibrescope has been correctly inserted into the trachea.^{38 42 50 60} The incidence of migration of a tube into the oesophageal inlet can be high: in one report, this occurred in four of 10 patients (40%),⁹ whereas in another study it occurred in eight of 13 patients (62%) when a tube was passed over a gum elastic bougie.³³ On 5–10% of occasions, migration of the tube into the oesophagus is unnoticed until the fibrescope is removed from the trachea.^{38 50}

A few possible reasons for deviation of the tip of the tube towards the oesophageal inlet have been suggested.⁵⁰ The first possibility is that a small part of the tip of the tube impinges on the laryngeal inlet and the tube then slips off into the oesophagus. The second possibility is that, when the tube is pulled back after it has been obstructed by the laryngeal inlet, the fibrescope may be pulled out of the trachea.⁵⁰ However, these are probably not the main causes. Asai and colleagues⁹ investigated the problem by using a second fibrescope to observe the passage of a tube, which was inserted nasally into the oral cavity: the tube never impinged on the arytenoid cartilage and slipped off into the oesophagus, but was always advanced directly into the oesophagus, ignoring the course of the fibrescope. In this study, it also became apparent that, in the case of inadvertent insertion of the tube into the oesophageal inlet, there may have been resistance while a tracheal tube was being advanced, because the tube was pushing the mid-segment of the fibrescope into the oesophagus, not because the tube was impinging on the arytenoid cartilage before slipping off into the oesophagus (Fig. 3A).⁹ The tracheal tube may be continually advanced into the oesophagus, pulling the fibrescope out of the trachea, over the interarytenoid notch and into the oesophagus (Fig. 3B).^{9 36 60}

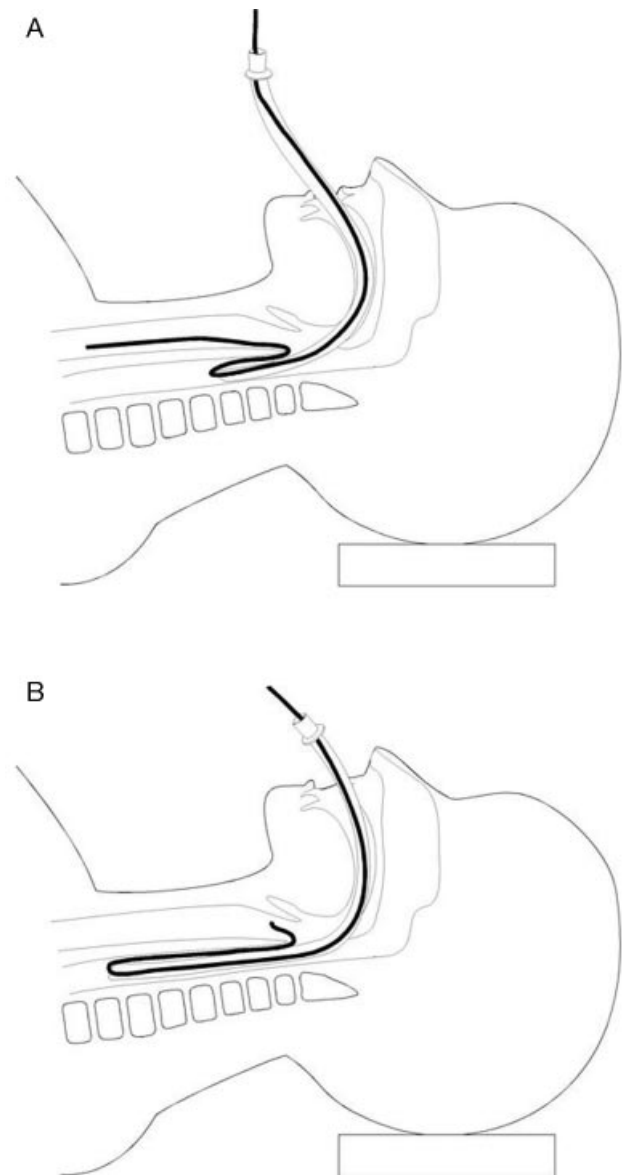


Fig 3 Schematic illustration of oesophageal intubation after correct insertion of a fibrescope into the trachea. (A) If the tip of a tracheal tube enters the oesophagus, the fibrescope is looped over the interarytenoid notch and over the tube tip. Resistance may be felt when advancing the tube because its tip is pushing the mid-segment of the fibrescope into the oesophagus. (B) As the tube is inserted deeper into the oesophagus, the fibrescope is pulled out of the trachea into the oesophagus.

Size of the tongue and epiglottis

The size of the tongue and the length of the epiglottis (which are measured on an X-ray image) are correlated with the incidence of impingement of a tube.⁷⁰

Other anatomical factors

Deformity of the upper airway or distortion of the airway (by an intrinsic or extrinsic tumour) has been reported to obstruct the passage of a tube over a fibrescope.^{35 40 83}

Size of fibrescopes and tracheal tubes

Several studies have shown that the sizes of the fibrescope and tracheal tube affect the ease of passage of a tube over a fibrescope. Basically, the greater the gap between a fibrescope and a tracheal tube, the higher the likelihood of difficulty in advancing a tube over a fibrescope (Fig. 1).^{50 57} The texture and shape of tracheal tubes can also alter the ease of intubation over a fibrescope. The details of these factors will be described in the next section, with possible solutions.

Murphy eye of a tube

If the tip of a fibrescope is inadvertently advanced through a side hole (Murphy eye) of a tracheal tube, it becomes impossible to advance the tube into the trachea (Fig. 4).⁶⁵

Airway intubator

Several airway intubators, such as the Ovassapian and Berman types, have been developed to facilitate insertion of a fibrescope into the trachea.^{41 68 72} However, an airway intubator may obstruct the passage of a tube over a fibrescope at its proximal edge,⁷² or by catching the cuff of the tube.^{41 68}

Cricoid pressure

In one report, cricoid pressure, which was applied during rapid-sequence induction of anaesthesia, obstructed passage of a tube over a fibrescope into the trachea in two of 30 patients.⁶⁸

Jaw thrusting

Thrusting the jaw forward widens the oropharyngeal cavity and opens the laryngeal inlet, thus easing insertion of a fibrescope into the trachea.^{1 61} On occasions, this manoeuvre may make it more difficult to pass a tube over the fibrescope into the trachea, however.³⁸ The reason for this is not clear, but one possibility is that thrusting the jaw forward shifts the larynx anteriorly and widens the oesophageal inlet so that the tube is more likely to be inserted into the inlet.

Solutions

Several methods have been suggested for reducing difficulty in advancing a tracheal tube over a fibrescope. A combination of these methods may be required to achieve smooth fibreoptic intubation, because several different anatomical sites and non-anatomical factors can obstruct the passage of a tube over a fibrescope.




Fig 4 If the tip of a fibrescope is inadvertently advanced through a side hole (Murphy eye) of a tracheal tube, it becomes impossible to advance the tube into the trachea.

Reduction of the gap between a fibrescope and a tracheal tube

One method of reducing the difficulty in advancing a tracheal tube over a fibrescope is to minimize the gap between the fibrescope and the tracheal tube. There are a few methods of achieving this: (i) use of a thick fibrescope and a thin tracheal tube; (ii) use of a tapered tube; and (iii) use of a gap-filler.

Use of a thick fibrescope and a thin tracheal tube

In one report, the ease of oral fibreoptic intubation was compared between an 8.0 mm ID and a 6.0 mm ID flexible tracheal tube.⁵⁰ When a 6.0 mm tracheal tube was used, it was easy to pass the tube over the fibrescope (diameter 4.0 mm) into the trachea in 11 patients (55%), whereas when an 8.0 mm tube was used it was only easy in two of 20 patients (10%).⁵⁰ Another study showed that the incidence of difficulty was lower using a thicker (diameter 5 mm) fibrescope (11%) than using a thinner (3.7 mm) scope (35%).³⁸ Therefore, the use of a fibrescope of large diameter and a tracheal tube of narrow diameter would reduce the incidence of difficulty in advancing the tube over the fibrescope.

Use of a tapered tracheal tube

The gap between a fibrescope and a tube can be reduced if the tip of the tube is tapered. Jones and colleagues⁴⁶ developed such a tube (the Moore tube), and showed that tracheal intubation with the Moore tube was much easier than intubation with a conventional tube. This tube is not commercially available.

Use of a gap-filler

Another way of reducing the gap between a tracheal tube and a fibrescope is to thread another, thinner tube into the tracheal tube. By cutting a 7.0-mm or 8.0-mm ID tube to the oral length of 23 cm, and by threading it over a well lubricated, uncuffed and uncut thinner tube (e.g. 5.0 mm




Fig 5 Insertion of a thinner tracheal tube between a larger tracheal tube and a fibroscope facilitates smooth passage into the trachea.

ID), the inner tube can protrude beyond the end of the outer tube (Fig. 5). When these two tubes are threaded over a fibroscope, the thinner tube fills the gap that otherwise exists between the outer tube and the fibroscope (Fig. 5). After successful insertion of the fibroscope and the two tubes into the trachea, the fibroscope and the inner tube are removed. In one report, in 30 patients in whom difficult laryngoscopy was predicted and there was resistance to advancement of a thick tracheal tube (7.0 or 8.0 mm ID) over an orally inserted fibroscope, advancing the thick tube over a thinner tube (5.0 mm ID) and over a fibroscope was smooth in all patients.⁵⁷ The effectiveness of this technique has been confirmed by another study.⁷³ Instead of using a thin tracheal tube, an especially tailored polyvinyl chloride sleeve can be used to fill the gap between a tracheal tube and a fibroscope.¹⁴ With this technique, the sleeve would not only fill the gap between the tube and the fibroscope, but also reduce the incidence of the fibroscope being looped over the tip of the tube.

Ayoub and colleagues¹³ used an airway exchange catheter as a gap-filler. They reported that insertion of a Cook airway exchange catheter through a tracheal tube alongside a fibroscope into the trachea made it easier to pass a tube over the fibroscope. The usefulness of this method is not clear, because the ease of passing the exchange catheter into the trachea is not known.

Use of the Parker Flex-Tip™ tube

The Parker Flex-Tip™ tracheal tube (Parker Medical, Englewood, CO, USA), which is a polyvinyl chloride tube and has a flexible tip positioned towards the centre of its distal lumen (Fig. 6), has been reported to be easier than the conventional polyvinyl chloride tube to pass over a fibroscope into the trachea (Fig. 1).^{15 51} In one report, tracheal intubation over a fibroscope was smooth in four of 38 patients (11%) when a conventional tube was used,

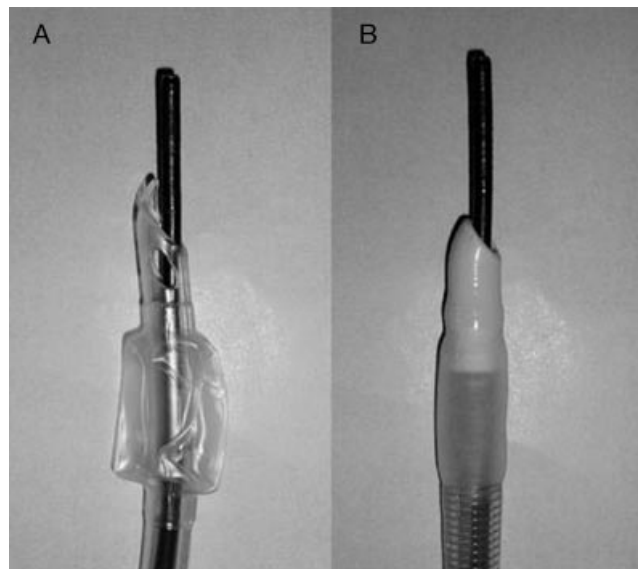


Fig 6 (A) The Parker Flex-Tip™ tracheal tube and (B) the intubating laryngeal mask airway tube.

whereas it was smooth in 27 of 38 patients (71%) when the Parker tube was used.⁵¹ Similarly, in another study with a cross-over design, fibreoptic intubation was successful at the first attempt in seven of 17 patients (41%) for the conventional tube and in 13 of 17 patients (76%) for the Parker tube.¹⁵ The ease of advancing a Parker tube over an airway exchange catheter has also been shown.⁵⁵

Two possible reasons for the advantage of the Parker tube over the conventional polyvinyl chloride tube can be considered. The first is the difference in the direction of the bevel between the Parker and conventional tubes. The bevel of the Parker tube is facing posteriorly, instead of to the left, so that the tip of the Parker tube is equivalent to a conventional tube being rotated 90° anticlockwise (see below for the advantage of anticlockwise rotation of a tube). The second possibility is that the flexible tip of the Parker tube reduces the gap between the fibroscope and the tube, facilitating intubation. Baraka and colleagues¹⁵ state that the first possibility seems to be the main reason, because the ease of fibreoptic intubation was not decreased even when the flexible tip had been cut off.

Use of a flexible tube

A flexible tube is easier than a polyvinyl chloride tube to pass over an orally inserted fibroscope into the trachea,^{24 25 41} because a flexible tube can change its direction more easily to follow the curve of a fibroscope (Fig. 1). In one study of 20 patients, when a polyvinyl chloride tube was used, fibreoptic intubation was successful at the first attempt in only seven of 20 patients (35%), whereas for a flexible tube it was successful in 19 of 20 patients (95%).²⁴

For nasal fibreoptic intubation, a flexible tube may not be as useful. In one study, there was no difficulty in advancing

a polyvinyl chloride tube in eight of 16 patients nasally and a flexible tube in nine out of 16 patients.¹⁶ The reason for this finding is not known.

Use of an ILM flexible tube

The intubating laryngeal mask airway tube is a tube originally designed to pass through the intubating laryngeal mask airway into the trachea. The bevel of this tube is made of silicone and is softer than the conventional polyvinyl chloride tube; the bevel is hemispherical, with the leading edge in the midline; and the tube is also more flexible than the conventional tube (Fig. 6). Several studies have shown that insertion of this tube over the fibroscope into the trachea (without the use of the intubating laryngeal mask airway) is almost always easy (90–100%) (Fig. 1).^{16 37 54} There has also been a report of two patients in whom insertion of a polyvinyl chloride tube over a fibroscope failed, but fibreoptic intubation using the intubating laryngeal mask airway tube was easy.³⁴

Warming of a tracheal tube

Several authors have suggested that fibreoptic intubation may become easier when a polyvinyl chloride tube is warmed (by hot water or hot air), because the tube becomes softer and thus more easily follows the curve of a fibroscope into the trachea.^{29 30 41 49} However, there has been no clear evidence to support or reject the usefulness of this idea. In one study, the ease of fibreoptic intubation was assessed for warmed and non-warmed polyvinyl chloride tubes.⁴¹ The non-warmed tube was easily inserted into the trachea in 10 of 30 patients (33%) and the warmed tubes in 18 of 30 patients (60%). This difference (27%) seems marked, but there was no significant difference between the two groups. It is possible that the number of patients studied was too small to detect a clinically meaningful difference (false negative). In another study, the ease of fibreoptic orotracheal intubation was assessed using flexible tubes and warmed polyvinyl chloride tubes.³⁰ Intubation was easy in 13 of 25 patients (52%) using flexible tubes and 17 of 25 patients (68%) using warmed polyvinyl chloride tubes; there was no significant difference between groups. This result might mean that tracheal intubation with a warmed polyvinyl chloride tube is as easy as intubation with a flexible tube, but it is not clear whether insertion of the warmed polyvinyl chloride tube is easier than insertion of a non-warmed tube.

Loading a tube over a fibroscope

When a tracheal tube is inserted into the nose or mouth and then an attempt is made to pass a fibroscope through the tube into the trachea, the tip of the fibroscope can pass through the side hole of the tube (Murphy eye) and tracheal intubation fail. This complication can be easily avoided

either by loading a tracheal tube over a fibroscope before attempting fibreoptic intubation, or by advancing a fibroscope under direct vision until the fibroscope has passed through the distal orifice of the tube. The latter method may be more suitable for nasal fibreoptic intubation, because with the former method it may not be possible to insert a tube loaded over a fibroscope through a narrowed nasal passage after successful insertion of the fibroscope into the trachea.²⁷

Removal of an airway intubator

Once the fibroscope has been inserted into the trachea, it may be better to remove an airway intubator (such as the Ovassapian airway), as it might hamper passage of a tracheal tube.^{41 68 72}

Rotation of a tube

When a bevelled tracheal tube is used, rotation reduces the difficulty in advancing a tube over a fibroscope,^{31 33 50} by reducing the incidence of impingement of the tube on the right arytenoid cartilage or the right vocal cord, of oesophageal intubation, or the tube sticking to the anterior surface of the subglottis.

Rotation of the tube at random might enable intubation, but 90° anticlockwise rotation should be most effective in reducing impingement on the tube.³¹ When a tracheal tube is advanced over a fibroscope, the bevel of the tube is facing the left and thus the tip of the tube is liable to impinge on the right arytenoid cartilage or the right vocal cord (Fig. 2). If the tube is rotated 90° clockwise (Fig. 7A), the tip of the tube lies posterior to the fibroscope and may become impinged behind the arytenoids. In contrast, 90° anticlockwise rotation of the tube brings it into close contact with the fibroscope, minimizing impingement (Fig. 7B).³¹ When the tube is rotated 180°, the tip of the tube is liable to impinge on the left arytenoid cartilage or the left vocal cord (Fig. 7C). Several studies have confirmed that 90° anticlockwise rotation of the tube decreases the likelihood of difficulty in advancing a tube over a fibroscope^{43 46 50 77} or gum elastic bougie.³³

Rotation of the tube should also reduce the incidence of inadvertent insertion of the tube into the oesophagus. When the tube is advanced without rotation, it tends to move towards the oesophageal inlet.⁹ Rotation of the tube changes its curvature to the side or posteriorly, and thus should decrease the incidence of oesophageal intubation. Lastly, when the tube is advanced without rotation, because of its natural curvature, the tip of the tube may adhere to the anterior inner surface of the subglottic area. Rotation of the tube should alter its direction and thus decrease the incidence of this problem.

Rotation of a tube may not be effective in some circumstances.^{16 38 50} This method may be less effective if a tracheal tube of a large diameter is used.^{38 50} In one

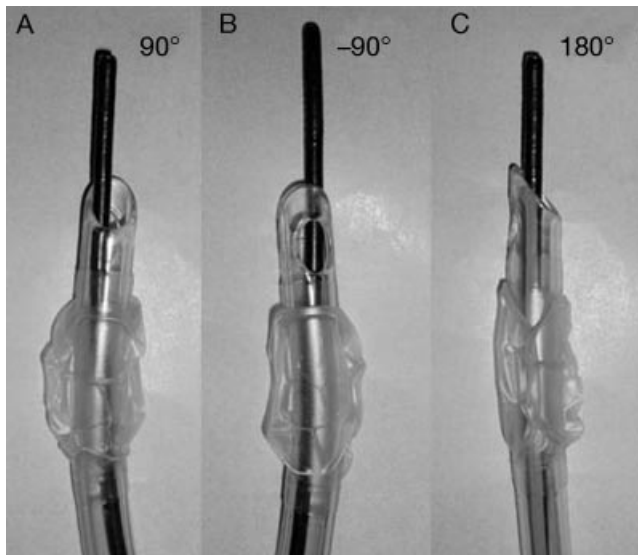


Fig 7 When a tracheal tube is advanced over a fibroscope, the bevel of the tube is facing the left and thus the tip of the tube is liable to impinge on the right arytenoid cartilage or the right vocal cord (Fig. 2). When the tube is rotated 90° clockwise (A), the tip of the tube lies posterior to the fibroscope, and may impinge behind the arytenoid cartilages. In contrast, 90° anticlockwise rotation of the tube brings it into close contact with the fibroscope, minimizing impingement (B). When the tube is rotated 180°(C), the tip of the tube is liable to impinge on the left arytenoid cartilage or the left vocal cord.

study, in which two sizes (6.0 and 8.0 mm ID) of flexible tube were used, there was resistance to advancing a 6.0 mm tube in nine of 20 patients and a 8.0 mm tube in 18 patients. Rotation of the 6.0 mm tube allowed intubation in eight of the nine patients (89%), whereas rotation of the 8.0 mm tube allowed intubation in only six of the 18 patients (33%).⁵⁰ Nor may rotation of the tube be effective for nasal fibreoptic intubation.¹⁶ This may result from the epiglottis being the main obstruction to smooth intubation in these circumstances, so that rotation of the tube would not solve the problem. Lastly, rotation in itself will not be effective if the tube has been inserted into the oesophageal inlet.⁹ Withdrawing the tube for a few centimetres will be necessary before rotating and advancing the tube into the trachea.⁵⁰

Release of jaw thrust

It may be better to release the jaw thrust when a tube is passed over a fibroscope, because jaw thrusting may increase the likelihood of difficulty in advancing a tube.³⁸

Flexion of the neck

Flexion of the neck may make it possible to intubate over a fibroscope when the tube cannot be advanced into the trachea despite rotation.³⁸ The explanation for this success-

ful manoeuvre is uncertain, but it might be that the tip of the tracheal tube is impinging on the anterior, inner surface of the subglottis and flexion of the neck relieves the problem.

Cricoid pressure

Another possible reason for difficulty in fibreoptic intubation is inadvertent oesophageal intubation. Thus, occlusion of the oesophageal inlet by application of pressure over the cricoid cartilage, in theory, increases the success rate of fibreoptic intubation. This has been confirmed by one study, in which patients were randomly allocated to receive either cricoid pressure (19 patients) or sham pressure (21 patients), and the success rate of oral fibreoptic intubation was assessed.⁹ When no pressure was applied to the cricoid cartilage, tracheal intubation was successful within 60 s in only seven of 21 patients (33%), whereas when cricoid pressure was applied, tracheal intubation was successful within 60 s in 12 of 19 patients (63%). In this study, polyvinyl chloride tubes were used, and thus it is not known how often cricoid pressure facilitates passage of a flexible tube over the fibroscope into the trachea. As cricoid pressure can also make it difficult to intubate,⁶⁸ it should be released and other techniques used if it is still difficult to advance a tube into the trachea.

Use of a laryngoscope

Oropharyngeal tissues, such as the root of the tongue or the epiglottis, may obstruct the passage of a tracheal tube over the fibroscope. Insertion of a laryngoscope may reduce the difficulty in passing a tube over a fibroscope, by lifting these tissues in an anterior direction and by opening up the glottis. In a study of patients without difficult airways, insertion of a tracheal tube over a fibroscope was difficult in six out of 10 patients even with rotation of the tube; in all of these patients, insertion of a laryngoscope enabled fibreoptic intubation.⁵⁰ Similar findings were found in another study, in which tracheal intubation over a gum elastic bougie was easier with the aid of a laryngoscope than without it.³³ Insertion of the McCoy laryngoscope and levering the tip of the blade allowed fibreoptic intubation in one patient in whom tracheal intubation using a laryngoscope had failed, and in whom a downfolded epiglottis prevented insertion of a tube over the fibroscope.⁷ As laryngoscopy also facilitates location of the glottis with the fibroscope and insertion of the scope into the trachea,^{32 45 75 76} a laryngoscope can be inserted before attempting fibreoptic intubation.

Use of digital aid

Tracheal intubation was achieved using the fingers until the Macintosh and Miller laryngoscopes were introduced into clinical practice.^{78 84} As with laryngoscopy, insertion of the

index finger into the vallecula to open up the glottis by shifting the epiglottis anteriorly may ease fibreoptic intubation. Successful use of this technique has been reported in a patient who required neck stabilization, in whom passage of a tube over the fibroscope into the trachea had failed even after several different manoeuvres, such as rotation of the tube.⁷

Viewing through, or movement of, a fibroscope

Inadvertent insertion of a tracheal tube into the oesophagus is one major cause of failure. Any method which can detect migration of the tube into the oesophageal inlet before inadvertent removal of a fibroscope from the trachea would be useful. In one method, the operator keeps looking through the fibroscope while advancing the tube over the scope until the tip of the tube comes into view.³⁶ If the tracheal carina goes out of view, the tube is likely to have migrated into the oesophagus. Nevertheless, many anaesthetists ask assistants to hold the fibroscope, so that they can hold the tracheal tube and flexible cord of the fibroscope, and do not look through the fibroscope during attempts at advancing the tube. A live video display of the fibreoptic view would solve this problem. Another method is to monitor capnography when advancing a tube.¹⁰ If the end-tidal carbon dioxide concentration becomes zero, the tip of the tube may have gone into the oesophageal inlet. When oesophageal intubation is suspected, the tube is pulled back before rotating and advancing it.

Use of the laryngeal mask airway

Classic laryngeal mask airway

The laryngeal mask airway has been widely used during anaesthesia, and it can also be used to facilitate tracheal intubation.^{4 23} Brain chose to attach a tube to the back of the mask at an angle of about 30°, because he had found that this was the optimal angle for tracheal intubation through the laryngeal mask.²⁰ He later developed the intubating laryngeal mask airway, especially for tracheal intubation through the device.^{21 22} Since the first description by Brain,¹⁹ there have been numerous reports of successful fibreoptic intubation through the laryngeal mask in patients who were known to be difficult to intubate^{3 79} or in whom tracheal intubation with both a laryngoscope and a fibreoptic bronchoscope had failed.^{4 53} By passing a fibroscope and a tube through the laryngeal mask airway, Silk and colleagues⁷⁹ intubated the trachea within 2 min in 46 of 48 patients with predicted difficult airways.

Fibreoptic intubation through the laryngeal mask airway has two major advantages over conventional fibreoptic intubation. First, the laryngeal mask facilitates location of the glottis using a fibroscope, because the glottis is usually positioned just below the grille of the mask and thus the distance between the grille and the vocal cords is only a few

centimetres.⁶ The second advantage is that the laryngeal mask reduces the incidence of difficulty in passing a tracheal tube over a fibroscope, because the laryngeal mask bypasses obstacles, such as a narrowed pharyngeal cavity or the epiglottis, and restricts lateral or posterior deviation of the tracheal tube from the glottis.^{2 50}

In one report, the ease of fibreoptic intubation with and without the use of the laryngeal mask was compared.⁵⁰ When conventional fibreoptic intubation (without the use of the laryngeal mask) was attempted, there was resistance in advancing the tube over the fibroscope in 11 of 20 patients (55%). In contrast, when the laryngeal mask was used for tracheal intubation over the fibroscope, intubation was always smooth. In addition, the time for insertion of the fibroscope into the trachea was a few seconds shorter with the use of the laryngeal mask than without, although the total time was a few seconds longer because of the time taken to insert the mask.⁵⁰

Intubating laryngeal mask airway

There have been several reports of successful intubation through the intubating laryngeal mask after failed or previously difficult fibreoptic tracheal intubation.^{11 35 47 53 86} One study has shown that, as with the classic laryngeal mask, the intubating laryngeal mask facilitates fibreoptic intubation. In that study, conventional fibreoptic intubation was easy in only 14 of 42 patients (33%), whereas fibreoptic intubation through the intubating laryngeal mask was easy in 27 of 42 patients (64%).⁵ The time for tracheal intubation over the fibroscope was significantly shorter with the use of the intubating laryngeal mask than without it.⁵

In one report of 57 patients with difficult airways in whom fibreoptic intubation through the intubating laryngeal mask was attempted, it was successful in all patients.³⁵ In another study of 100 patients with anticipated difficult intubation, fibreoptic intubation with and without the use of the intubating laryngeal mask was studied. The success rate and time for intubation were similar for the two methods, but complications (such as bleeding or hypoxia) were significantly lower with the use of the intubating laryngeal mask.⁵³ In these two studies, the ease of passing the tube over a fibroscope was not specifically mentioned.

The intubating laryngeal mask may be particularly useful when movement of the patient's neck is restricted. In one study in which the patient's neck was stabilized by the manual in-line method, and when conventional fibreoptic intubation was attempted, a fibroscope could be inserted into the trachea within 2 min in only eight of 20 patients (40%).⁵ In contrast, when a fibroscope was inserted through the intubating laryngeal mask, it was possible to insert the fibroscope into the trachea in 19 of 20 patients (95%). Passing a tracheal tube over a fibroscope was also markedly easier with the use of the intubating laryngeal mask than without it. Intubation was easy in four of 20 patients (20%) without the use of the laryngeal mask, whereas it was easy in 13 of 20 patients (65%) with its use.⁵ In one report of 20

patients with unstable necks, fibreoptic intubation through the intubating laryngeal mask was successful in all patients.¹²

The trachea can be intubated blindly through the intubating laryngeal mask with a high success rate,^{21 35} and in patients with difficult airways the rate was similar to, or even greater than, that in patients with normal airways.²¹ Therefore, it is conceivable that fibreoptic intubation may become easier by using the intubating laryngeal mask in patients with difficult airways. Nevertheless, it has not been confirmed that the intubating laryngeal mask makes the passage of a tube over a fibrescope easier in this group.

Conclusions

Since Murphy reported its use for tracheal intubation in 1967,^{25 62} fibroscopy has become established in the management of difficult airways. Nevertheless, some anaesthetists have difficulty in advancing a tube over a fibrescope on 90% of occasions. There are several factors which would alter the incidence, but the most obvious is the type of tracheal tube used. It is apparent from Figure 1 that the incidence is high when a conventional polyvinyl chloride tube is used, and can be markedly reduced by using a flexible tube.

To decrease the likelihood of difficulty, we recommend taking the following measurements routinely. Use a thick fibrescope and a thin tracheal tube, such as one with an internal diameter of 6.0 mm. A flexible tracheal tube (or Parker Flex-Tip tube) should be used. Before attempting intubation, the tube should be loaded over the fibrescope to prevent the fibrescope inadvertently passing through the Murphy eye of the tube. The laryngeal mask airway or the intubating laryngeal mask airway may be inserted to facilitate fibreoptic intubation.

Once the fibrescope has been inserted into the trachea, any airway intubator should be removed. When there is difficulty in advancing a tube, withdraw the tube for a few centimetres, rotate it 90° anticlockwise (when a bevelled tube is used), and re-advance it. When advancing the tube, the view through the fibrescope should be monitored continuously, either by a second person or by viewing it on a video screen. If it is still difficult to advance the tube it may be rotated by 180°, and the position of the head and neck adjusted, cricoid pressure applied, or a laryngoscope inserted before another attempt at intubation is made. If it is still difficult, repetitive attempts should be avoided and other options, including avoidance of tracheal intubation or cancellation of surgery, should be considered.

Although the causes of difficulty in tracheal intubation over a fibrescope and the inefficacy of each solution have not been elucidated fully, it is essential at least to choose an appropriate fibrescope and tracheal tube and to apply appropriate manoeuvres, to make fibreoptic intubation safer.

References

- 1 Aoyama K, Takenaka I, Nagaoka E, Kadoya T. Jaw thrust maneuver for endotracheal intubation using a fiberoptic stylet. *Anesth Analg* 2000; **90**: 1457–8
- 2 Asai T. Use of the laryngeal mask for tracheal intubation in patients at increased risk of aspiration of gastric contents. *Anesthesiology* 1992; **77**: 1029–30
- 3 Asai T. Fiberoptic tracheal intubation through the laryngeal mask in an awake patient with cervical spine injury. *Anesth Analg* 1993; **77**: 404
- 4 Asai T. Use of the laryngeal mask for fibrescope-aided tracheal intubation in an awake patient with deviated larynx. *Acta Anaesthesiol Scand* 1994; **38**: 615–6
- 5 Asai T, Eguchi Y, Murao K, Niitsu T, Shingu K. Intubating laryngeal mask for fibreoptic intubation—particularly useful during neck stabilization. *Can J Anaesth* 2000; **47**: 843–8
- 6 Asai T, Latto IP, Vaughan RS. The distance between the grille of the laryngeal mask airway and the vocal cords. Is conventional intubation through the laryngeal mask safe? *Anaesthesia* 1993; **48**: 667–9
- 7 Asai T, Matsumoto S, Shingu K. Use of the McCoy laryngoscope or fingers to facilitate fibrescope-aided tracheal intubation. *Anaesthesia* 1998; **53**: 903–5
- 8 Asai T, Morris S. The laryngeal mask airway: its features, effects and role. *Can J Anaesth* 1994; **41**: 930–60
- 9 Asai T, Murao K, Johmura S, Shingu K. Effect of cricoid pressure on the ease of fibrescope-aided tracheal intubation. *Anaesthesia* 2002; **57**: 909–13
- 10 Asai T, Murao K, Shingu K. Capnography during fibreoptic intubation. *Anaesthesia* 2003; **58**: 1131
- 11 Asai T, Shingu K. Tracheal intubation through the intubating laryngeal mask in a patient with a fixed flexed neck and deviated larynx. *Anaesthesia* 1998; **53**: 1199–201
- 12 Asai T, Shingu K. Tracheal intubation through the intubating laryngeal mask in patients with unstable necks. *Acta Anaesthesiol Scand* 2001; **45**: 818–22
- 13 Ayoub CM, Lteif AM, Rizk MS, Abu Jalad NM, Hadi U, Baraka AS. Facilitation of passing the endotracheal tube using a Cook airway exchange catheter. *Anesthesiology* 2002; **96**: 1517–8
- 14 Ayoub CM, Rizk MS, Yaacoub CI, Baraka AS, Lteif AM. Advancing the tracheal tube over a flexible fiberoptic bronchoscope by a sleeve mounted on the insertion cord. *Anesth Analg* 2003; **96**: 290–2
- 15 Baraka A, Rizk M, Muallem M, Bizri SH, Ayoub C. Posterior-beveled vs lateral-beveled tracheal tube for fibreoptic intubation. *Can J Anaesth* 2002; **49**: 889–90
- 16 Barker KF, Bolton P, Cole S, Coe PA. Ease of laryngeal passage during fibreoptic intubation: a comparison of three endotracheal tubes. *Acta Anaesthesiol Scand* 2001; **45**: 624–6
- 17 Berman RA. A method for blind oral intubation of the trachea or esophagus. *Anesth Analg* 1977; **56**: 866–7
- 18 Bonner S, Taylor M. Airway obstruction in head and neck surgery. *Anaesthesia* 2000; **55**: 290–1
- 19 Brain Al. Three cases of difficult intubation overcome by the laryngeal mask airway. *Anaesthesia* 1985; **40**: 353–5
- 20 Brain Al. The development of the Laryngeal Mask—a brief history of the invention, early clinical studies and experimental work from which the Laryngeal Mask evolved. *Eur J Anaesthesiol* 1991; Suppl 4: 5–17
- 21 Brain Al, Verghese C, Addy EV, Kapila A. The intubating laryngeal mask. I: Development of a new device for intubation of the trachea. *Br J Anaesth* 1997; **79**: 699–703
- 22 Brain AlJ, Verghese C, Addy EV, Kapila A, Brimacombe J. The

- intubating laryngeal mask. II: a preliminary clinical report of a new means of intubating the trachea. *Br J Anaesth* 1997; **79**: 704–9
- 23 Brimacombe JR, Brain AlJ, Berry A. *The Laryngeal Mask Airway. Instruction Manual*, 3rd Edn. Pangbourne: Intavent-Orthofix, 1996
 - 24 Brull SJ, Wiklund R, Ferris C, Connelly NR, Ehrenwerth J, Silverman DG. Facilitation of fiberoptic orotracheal intubation with a flexible tracheal tube. *Anesth Analg* 1994; **78**: 746–8
 - 25 Calder I. When the endotracheal tube will not pass over the flexible fiberoptic bronchoscope. *Anesthesiology* 1992; **77**: 398
 - 26 Calder I, Pearce A, Towey R. Classic paper: a fiberoptic endoscope used for tracheal intubation. *Anaesthesia* 1996; **51**: 602
 - 27 Cherala S, Ovassapian A. A complication of fiberoptic nasal tracheal intubation. *Anesth Analg* 1989; **71**: 319
 - 28 Coe PA, King TA, Towey RM. Teaching guided fiberoptic nasotracheal intubation. An assessment of an anaesthetic technique to aid training. *Anaesthesia* 1988; **43**: 410–3
 - 29 Cole AF. Fiberoptic intubation. *Can J Anaesth* 1993; **40**: 469–70
 - 30 Connelly NR, Kyle R, Gotta J, et al. Comparison of wire reinforced tubes with warmed standard tubes to facilitate fiberoptic intubation. *J Clin Anesth* 2001; **13**: 3–5
 - 31 Cossham PS. Difficult intubation. *Br J Anaesth* 1985; **57**: 239
 - 32 Couture P, Perreault C, Girard D. Fiberoptic bronchoscopic intubation after induction of general anaesthesia: another approach. *Can J Anaesth* 1992; **39**: 99
 - 33 Dogra S, Falconer R, Latto IP. Successful difficult intubation. Tracheal tube placement over a gum-elastic bougie. *Anaesthesia* 1990; **45**: 774–6
 - 34 Erickson KM, Keegan MT, Kamath GS, Harrison BA. The use of the intubating laryngeal mask endotracheal tube with intubating device. *Anesth Analg* 2002; **95**: 249–50
 - 35 Ferson DZ, Rosenblatt WH, Johansen MJ, Osborn I, Ovassapian A. Use of the intubating LMA-Fastrach in 254 patients with difficult-to-manage airways. *Anesthesiology* 2001; **95**: 1175–81
 - 36 Greer CG. Improved technique for fiberoptic intubation. *Anesthesiology* 1986; **64**: 835
 - 37 Greer JR, Smith SP, Strang T. A comparison of tracheal tube tip designs on the passage of an endotracheal tube during oral fiberoptic intubation. *Anesthesiology* 2001; **94**: 729–31
 - 38 Hakala P, Randall T. Comparison between two fibrescopes with different diameter insertion cords for fiberoptic intubation. *Anaesthesia* 1995; **50**: 735–7
 - 39 Hakala P, Randell T, Meretoja OA, Rintala R. Orotracheal fiberoptic intubation in children under general anaesthesia. *Paediatr Anaesth* 1997; **7**: 371–4
 - 40 Hakala P, Randell T, Valli H. Laryngoscopy and fiberoptic intubation in acromegalic patients. *Br J Anaesth* 1998; **80**: 345–7
 - 41 Hakala P, Randell T, Valli H. Comparison between tracheal tubes for orotracheal fiberoptic intubation. *Br J Anaesth* 1999; **82**: 135–6
 - 42 Heidegger T, Gerig HJ, Ulrich B, Schnider TW. Structure and process quality illustrated by fiberoptic intubation: analysis of 1612 cases. *Anaesthesia* 2003; **58**: 734–9
 - 43 Hughes S, Smith JE. Nasotracheal tube placement over the fiberoptic laryngoscope. *Anaesthesia* 1996; **51**: 1026–8
 - 44 Hung OR. Misconception of tracheal intubation using a fiberoptic bronchoscope. *Can J Anaesth* 1998; **45**: 496
 - 45 Johnson C, Hunter J, Ho E, Bruff C. Fiberoptic intubation facilitated by a rigid laryngoscope. *Anesth Analg* 1991; **72**: 714
 - 46 Jones HE, Pearce AC, Moore P. Fiberoptic intubation. Influence of tracheal tube tip design. *Anaesthesia* 1993; **48**: 672–4
 - 47 Joo H, Rose K. Fastrach—a new intubating laryngeal mask airway: successful use in patients with difficult airways. *Can J Anaesth* 1998; **45**: 253–6
 - 48 Katsnelson T, Frost EAM, Farcon E, Goldiner PL. When the endotracheal tube will not pass over the flexible fiberoptic bronchoscope. *Anesthesiology* 1992; **76**: 151–2
 - 49 Klapka JM. Flexible tracheal tubes facilitate fiberoptic intubation. *Anesth Analg* 1994; **79**: 1211–2
 - 50 Koga K, Asai T, Latto IP, Vaughan RS. Effect of size of a tracheal tube and the efficacy of the use of the laryngeal mask for fibrescope-aided tracheal intubation. *Anaesthesia* 1997; **52**: 131–5
 - 51 Kristensen MS. The Parker Flex-Tip tube versus a standard tube for fiberoptic orotracheal intubation: a randomized double-blind study. *Anesthesiology* 2003; **98**: 354–8
 - 52 Kuzma PJ, Calkins MD, Kline MD, Karan SM, Matson MD. The anesthetic management of patients with multiple pterygium syndrome. *Anesth Analg* 1996; **83**: 430–2
 - 53 Langeron O, Semjen F, Bourgain JL, Marsac A, Cros AM. Comparison of the intubating laryngeal mask airway with the fiberoptic intubation in anticipated difficult airway management. *Anesthesiology* 2001; **94**: 968–72
 - 54 Lucas DN, Yentis SM. A comparison of the intubating laryngeal mask tracheal tube with a standard tracheal tube for fiberoptic intubation. *Anaesthesia* 2000; **55**: 358–61
 - 55 Makino H, Katoh T, Kobayashi S, Bito H, Sato S. The effects of tracheal tube tip design and tube thickness on laryngeal pass ability during oral tube exchange with an introducer. *Anesth Analg* 2003; **97**: 285–8
 - 56 Marian F, Spiss CK, Hiesmayr M, Draxler V. [Non-invasive pulse oximetry for monitoring fiberoptic intubation]. (Article in German.) *Anaesthesist* 1985; **34**: 630–5
 - 57 Marsh NJ. Easier fiberoptic intubations. *Anesthesiology* 1992; **76**: 860–1
 - 58 Mason RA. Learning fiberoptic intubation: fundamental problems. *Anaesthesia* 1992; **47**: 729–31
 - 59 McGuire G, El-Beheiry H. Complete upper airway obstruction during awake fiberoptic intubation in patients with unstable cervical spine fractures. *Can J Anaesth* 1999; **46**: 176–8
 - 60 Moorthy SS, Dierdorf SF. An unusual difficulty in fiberoptic intubation. *Anesthesiology* 1985; **63**: 229
 - 61 Murashima K, Fukutome T. Effect of jaw-thrust manoeuvre on the laryngeal inlet. *Anaesthesia* 1998; **53**: 203–4
 - 62 Murphy P. A fibre-optic endoscope used for nasal intubation. *Anaesthesia* 1967; **22**: 489–91
 - 63 Nakayama M, Kataoka N, Usui Y, Inase N, Takayama S, Miura H. Techniques of nasotracheal intubation with the fiberoptic bronchoscope. *J Emerg Med* 1992; **10**: 729–34
 - 64 Nandi PR, Charlesworth CH, Taylor SJ, Nunn JF, Dore CJ. Effect of general anaesthesia on the pharynx. *Br J Anaesth* 1991; **66**: 157–62
 - 65 Nichols KP, Zornow MH. A potential complication of fiberoptic intubation. *Anesthesiology* 1989; **70**: 562–3
 - 66 Ovassapian A. *Fiberoptic Endoscopy and the Difficult Airway*, 2nd Edn. New York: Lippincott-Raven, 1996
 - 67 Ovassapian A, Yelich SJ, Dykes MHM, Brunner EE. Fiberoptic nasotracheal intubation-incidence and causes of failure. *Anesth Analg* 1983; **62**: 692–5
 - 68 Pandit JJ, Dravid RM, Iyer R, Popat MT. Orotracheal fiberoptic intubation for rapid sequence induction of anaesthesia. *Anaesthesia* 2002; **57**: 123–7
 - 69 Popat M. *Practical Fiberoptic Intubation*. Oxford: Butterworth Heinemann, 2001
 - 70 Randell T, Hakala P, Kytta J, Kinnunen J. The relevance of clinical and radiological measurements in predicting difficulties in fiberoptic orotracheal intubation in adults. *Anaesthesia* 1998; **53**: 1144–7

- 71 Randell T, Valli H, Hakala P. Comparison between the Ovassapian intubating airway and the Berman intubating airway in fibreoptic intubation. *Eur J Anaesthesiol* 1997; **14**: 380–4
- 72 Rogers SN, Benumof JL. New and easy techniques for fiberoptic endoscopy-aided tracheal intubation. *Anesthesiology* 1983; **59**: 569–72
- 73 Rosenblatt WH. Overcoming obstruction during bronchoscope-guided intubation of the trachea with the double setup endotracheal tube. *Anesth Analg* 1996; **83**: 175–7
- 74 Roth AG, Wheeler M, Stevenson GW, Hall SC. Comparison of a rigid laryngoscope with the ultrathin fibreoptic laryngoscope for tracheal intubation in infants. *Can J Anaesth* 1994; **41**: 1069–73
- 75 Russell SH, Hirsch NP. Simultaneous use of two laryngoscopes. *Anaesthesia* 1993; **48**: 918
- 76 Ryder W. Two cautionary tales. *Anaesthesia* 1994; **49**: 180–1
- 77 Schwartz D, Johnson C, Roberts J. A maneuver to facilitate flexible fiberoptic intubation. *Anesthesiology* 1989; **71**: 470–1
- 78 Siddall WJW. Tactile orotracheal intubation. *Anaesthesia* 1966; **21**: 221–2
- 79 Silk JM, Hill HM, Calder I. Difficult intubation and the laryngeal mask. *Eur J Anaesthesiol* 1991; **4** (Suppl.): 47–51
- 80 Smith JE. Heart rate and arterial pressure changes during fibreoptic tracheal intubation under general anaesthesia. *Anaesthesia* 1988; **43**: 629–32
- 81 Smith JE, Mackenzie AA, Sanghera SS, Scott-Knight VC. Cardiovascular effects of fibrescope-guided nasotracheal intubation. *Anaesthesia* 1989; **44**: 907–10
- 82 Smith JE, Mackenzie AA, Scott-Knight VCE. Comparison of two methods of fibrescope-guided tracheal intubation. *Br J Anaesth* 1991; **66**: 546–50
- 83 Sprung J, Weingarten T, Dilger J. The use of WuScope fiberoptic laryngoscopy for tracheal intubation in complex clinical situations. *Anesthesiology* 2003; **98**: 263–5
- 84 Sykes WS. Oral endotracheal intubation without laryngoscopy: a plea for simplicity. *Anesth Analg* 1937; **16**: 133–6
- 85 Vaughan RS. Training in fibreoptic laryngoscopy. *Br J Anaesth* 1991; **66**: 538–40
- 86 Watson NC, Hokanson M, Maltby JR, Todesco JM. The intubating laryngeal mask airway in failed fibreoptic intubation. *Can J Anaesth* 1999; **46**: 376–8
- 87 Williams RT, Maltby JR. Airway intubator. *Anesth Analg* 1982; **61**: 309
- 88 Wrigley SR, Black AE, Sidhu VS. A fibreoptic laryngoscope for paediatric anaesthesia. A study to evaluate the use of the 2.2 mm Olympus (LF-P) intubating fibrescope. *Anaesthesia* 1995; **50**: 709–12
- 89 Wulf H, Brinkmann G, Rautenberg M. Management of the difficult airway. A case of failed fiberoptic intubation. *Acta Anaesthesiol Scand* 1997; **41**: 1080–2